This international standard was developed in accordance with internationally recognized principles on standardization established in the Decision on Principles for the Development of International Standards, Guides and Recommendations issued by the World Trade Organization Technical Barriers to Trade (TBT) Committee.

Designation: F2978 – 20

Standards Guide to Optimize Scan Sequences for Clinical Diagnostic Evaluation of Metal-on-Metal Hip Arthroplasty Devices using Magnetic Resonance Imaging[1]

This standard is issued under the fixed designation F2978; the number immediately following the designation indicates the year of original adoption or, in the case of revision, the year of last revision. A number in parentheses indicates the year of last reapproval. A superscript epsilon (ε) indicates an editorial change since the last revision or reapproval.

1. Scope

1.1 This guide describes the recommended protocol for magnetic resonance imaging (MRI) studies of patients implanted with metal-on-metal (MOM) devices to determine if the periprosthetic tissues are likely to be associated with an adverse local tissue reaction (ALTR). Before scanning a patient with a specific implant, the MR practitioner shall confirm that the device is MR Conditional and that the scan protocol to be used satisfies the conditions for safe scanning for the specific implant. This guide assumes that the MRI protocol will be applied to MOM devices while they are implanted inside the body. It is also expected that standardized MRI safety measures will be followed during the performance of this scan protocol.

1.2 This guide covers the clinical evaluation of the tissues surrounding MOM hip replacement devices in patients using MRI. This guide is applicable to both total and resurfacing MOM hip systems.

1.3 The protocol contained in this guide applies to whole body magnetic resonance equipment, as defined in section 201.3.239 of IEC 60601-2-33, Ed. 3.2, with a whole body radiofrequency (RF) transmit coil as defined in section 201.3.240. The RF coil should have circulary polarized RF excitation (also commonly referred to as quadrature excitation) as defined in section 201.3.249 of IEC 60601-2-33, Ed. 3.2..

1.4 The values stated in SI units are to be regarded as standard.

1.5 *This standard does not purport to address all of the safety concerns, if any, associated with its use. It is the responsibility of the user of this standard to establish appropriate safety, health, and environmental practices and determine the applicability of regulatory limitations prior to use. The user may consider all precautions and warnings provided in the MR system and hip implant labeling prior to determining the applicability of these protocols.*

1.6 *This international standard was developed in accordance with internationally recognized principles on standardization established in the Decision on Principles for the Development of International Standards, Guides and Recommendations issued by the World Trade Organization Technical Barriers to Trade (TBT) Committee.*

2. Referenced Documents

2.1 *ASTM Standards:*[2]

A340 Terminology of Symbols and Definitions Relating to Magnetic Testing

F2503 Practice for Marking Medical Devices and Other Items for Safety in the Magnetic Resonance Environment

2.2 *IEC Standard:*[3]

IEC 60601-2-33:2010+AMD1:2013+AMD2:2015 CSV Medical electrical equipment—Part 2: Particular requirements for the basic safety and essential performance of magnetic resonance equipment for medical diagnosis, 2015

3. Terminology

3.1 *Definitions—For the purposes of this standard the following definitions shall apply:*

3.1.1 *Magnetic Resonance Imaging (MRI)*—diagnostic imaging technique that uses static and time-varying magnetic fields to provide tomographic images of tissue by the magnetic resonance of nuclei.

3.1.2 *MR-Conditional*—an item with demonstrated safety in the MR environment within defined conditions. At a minimum, address the conditions of the static magnetic field, the switched gradient magnetic field and the radiofrequency fields. Additional conditions, including specific configurations of the item, may be required (Practice F2503 – 13).

[1] This guide is under the jurisdiction of ASTM Committee F04 on Medical and Surgical Materials and Devices and is the direct responsibility of Subcommittee F04.22 on Arthroplasty.

Current edition approved Sept. 1, 2020. Published October 2020. Originally approved in 2013. Last previous edition approved in 2013 as F2978 – 13. DOI: 10.1520/F2978-20.

[2] For referenced ASTM standards, visit the ASTM website, www.astm.org, or contact ASTM Customer Service at service@astm.org. For *Annual Book of ASTM Standards* volume information, refer to the standard's Document Summary page on the ASTM website.

[3] Available from International Electrotechnical Commission (IEC), 3, rue de Varembé, P.O. Box 131, CH-1211 Geneva 20, Switzerland, http://www.iec.ch.

Copyright © ASTM International, 100 Barr Harbor Drive, PO Box C700, West Conshohocken, PA 19428-2959. United States

Documents
Document Sharing Hub

Full document details: ASTM F2978-20

3.1.3 *Metal-on-Metal (MOM) hip replacement*—a hip arthroplasty device in which the articulating surfaces of the femoral head and the acetabular cup are fabricated from metal.

4. Summary of Protocol

4.1 Surface coil fast spin echo (FSE), also known as turbo spin echo (TSE), sequences of the affected hip in three planes and a larger field-of-view (FOV) short tau inversion recovery (STIR) sequence to include both hips and the surrounding pelvis are recommended. A large FOV sequence of the entire pelvis should be included to assess for remote causes of pain, such as pelvic or sacral fractures, which may be referred to the hip.

4.2 With regards to the FSE, also known as turbo spin echo (TSE), surface coil imaging, an intermediate echo time, water-sensitive fast spin echo technique is effective in highlighting osteolysis and detecting wear-induced synovitis. The fluid-sensitive inversion recovery sequence helps outline fluid collections and will demonstrate the presence of marrow edema in the setting of implant loosening or peri-prosthetic fracture (**1**).[4]

4.3 Modifications of standard pulse sequence parameters should be applied when imaging in the presence of metallic implants. Options available to reduce susceptibility artifacts on routine clinical scanners include increasing the amplitude of the readout gradient by the use of a wider receiver bandwidth and thinner slices (**2, 3**). Decreasing voxel size by the use of a high-resolution matrix will increase spatial resolution and trabecular detail in the face of the susceptibility artifact. However, these techniques will also decrease the signal-to-noise ratio. Orienting the frequency encoding direction along the long axis of the prosthesis can also be effective in decreasing artifacts but may not be feasible (**4**). In addition, view-angle tilting (VAT) gradients can be applied, which applies a section-selection gradient during the signal readout can be used (**5**).

4.4 Techniques to avoid when imaging in the presence of metal include imaging at high field strengths, use of frequency-selective fat suppression and use of gradient echo sequences. Artifact due to susceptibility is directly proportional to the main magnetic field (B_0); therefore, imaging at field strengths of 1.5 T or less are preferable where appropriate. Users should validate use of higher field strength when applicable to show comparison to the 1.5 T for lack of increased artifact susceptibility. When fat suppression is required, inversion recovery sequences are preferred over frequency-selective fat suppression techniques, as they are less susceptible to magnetic field inhomogeneities. Standardized gradient echo imaging should be avoided, as these sequences lack the 180° refocusing pulse of spin echo sequences, resulting in rapid dephasing of spins and large areas of signal void in the presence of metal.

4.5 Table 1 outlines a suggested protocol for imaging MOM hip arthroplasty using a 1.5 Tesla (T) clinical scanner where FSE and TSE are considered equal for parameter picks (**6**). The use of a 3 T MRI scanner is also an option but may not be

[4] The boldface numbers in parentheses refer to a list of references at the end of this standard.

TABLE 1 Suggested Protocol for Metal-on-Metal Hip Arthroplasty Imaging at a 1.5 T MRI Scanner [A,B]

Timing Parameters	Axial FSE/TSE	Coronal FIR	Coronal FSE/TSE	Axial FSE/TSE	Sagittal FSE/TSE
Coil	Body Coil	Body Coil	Surface Coil	Surface Coil	Surface Coil
TR, msec	4500 – 5500	4500	4500 – 5800	4500 – 5500	5500 – 6500
TE, msec	21.4 - 32.0	18	24 - 30	24 - 30	23 - 30
TI, msec	. . .	150	. . .	. . .	. . .
Echo train length	16 – 20	7 – 9	10 – 20	10 – 20	14 – 20
BW, kHz	83 – 125	83 – 125	83 – 125	83 – 125	83 – 125
FOV, cm	32 – 36	34 – 36	18	17 – 19	18 – 20
Matrix (or resolution in mm to be calculated by user spec)	512 × 256	256 × 192	512 × 352	512 × 256 - 288	512 × 352
Slice thickness, mm	5	5	4	4	2.5 – 3
Interslice gap, mm	0	0	0	0	0
Number of averages	4	2	4	4	4
No phase wrap (Fold-over suppression, by oversampling)	yes	yes	yes	yes	yes
Swap phase and frequency	yes	yes	yes	yes	yes
Variable BW	yes	yes	yes	yes	yes
Frequency direction (read-out direction)	anterior to posterior	right to left	right to left	anterior to posterior	anterior to posterior

[A] *Abbreviations:*
BW – bandwidth.
FIR – fast inversion recovery.
FOV – field of view.
FSE – fast spin echo.
TSE – turbo spin echo.
KHz – kiloHertz.
TE – echo time.
TI – inversion time.
TR – repetition time.

[B] Depending on the MRI system, the BW may be reported as half-bandwidth (maximum frequency), so a reported BW of 62.5 is actually acquired at 125 Hz over the entire frequency range. For Table 1, to convert to Hz/pixel when implementing 512 frequency encoding steps, use the following formula: (kHz x 2000)/512.

AVA Documents
Document Sharing Hub

Full document details: ASTM F2978-20

preferable and the recommendation in 4.4 should be considered. The protocol should be carefully considered for this option before proceeding.

4.6 Examples of three-dimensional multispectral imaging (3D-MSI) include multi-acquisition variable-resonance image combination (MAVRIC SL). Fourier transform-based spin-warp (WARP) and metal artifact reduction for orthopedic implants (O-MAR XD) that results in an image with markedly reduced susceptibility artifact (**7-11**). All 3D-MSI techniques utilize a VAT pulse to decrease frequency-encoding distortions and further utilize multiple frequency bins to mitigate through plane distortions. Early studies have demonstrated decreased image distortion at the bone-implant interface and improved detection of peri-prosthetic osteolysis and synovitis when compared to conventional fast spin echo techniques (**12**). A published study of patients with either MOM resurfacing or MOM total hip arthroplasty demonstrated synovitis using the MAVRIC sequence in 77.4 % of resurfacing arthroplasty and 86.2 % of total hip arthroplasty (THA) hips (**13, 14**). For imaging MOM arthroplasty, the use of a MAVRIC sequence is recommended in at least one plane (coronal or axial) when this sequence is available. When combined with an inversion pulse, they provide optimal fat suppression in the presence of implants. Specific parameters are listed in Appendix X2. With regards to timing, these protocols have been successful in assessing patients for both immediate and delayed complications, including fracture, nerve impingement, and tendon tears in the immediate post-operative period, and adverse tissue reactions, infection, and potential loosening in the later post-operative period (**6, 15, 16**). Additional 3D MSI sequences were developed and are available for such imaging, including slice encoding for metal artifact correction (SEMAC) (**9, 17**), known commercially as advanced WARP (**18**) and O-MAR XD.

5. Significance and Use

5.1 Magnetic resonance imaging is ideally suited to image MOM hip arthroplasty due to its superior soft tissue contrast, multiplanar capabilities and lack of ionizing radiation. MR imaging is the most accurate imaging modality for the assessment of peri-prosthetic osteolysis and wear-induced synovitis (**19, 20**).

5.2 Before scanning a patient with a specific implant, the MR practitioner shall confirm that the device is MR Conditional and that the scan protocol to be used satisfies the conditions for safe scanning for the specific implant.

5.3 This guide can be used to identify the following adverse events.

5.3.1 *Osteolysis*—Magnetic resonance imaging is superior to conventional radiographs and computer tomography (CT) in the assessment of peri-prosthetic osteolysis and has been shown to be the most accurate method to locate and quantify the extent of peri-prosthetic osteolysis (**19, 21**). On MR imaging, osteolysis appears as well marginated intraosseous intermediate to slightly increased signal intensity lesions that contrast with the high signal intensity of the intramedullary fat. A characteristic line of low signal intensity surrounds the area of focal marrow replacement, distinguishing the appearance of osteolysis from tumoral replacement of bone or infection (**22**).

5.3.2 *Component Loosening*—While the data are preliminary, MR imaging can identify circumferential bone resorption that may indicate component loosening. Loosening may result from osteolysis, circumferential fibrous membrane formation or poor osseous integration of a non-cemented component. On MR imaging, component loosening typically manifests as circumferential increased signal intensity at the metallic-bone or cement-bone interface on fat-suppressed techniques (**20**). The finding of circumferential fibrous membrane formation or osteolysis also indicates potential loosening; this

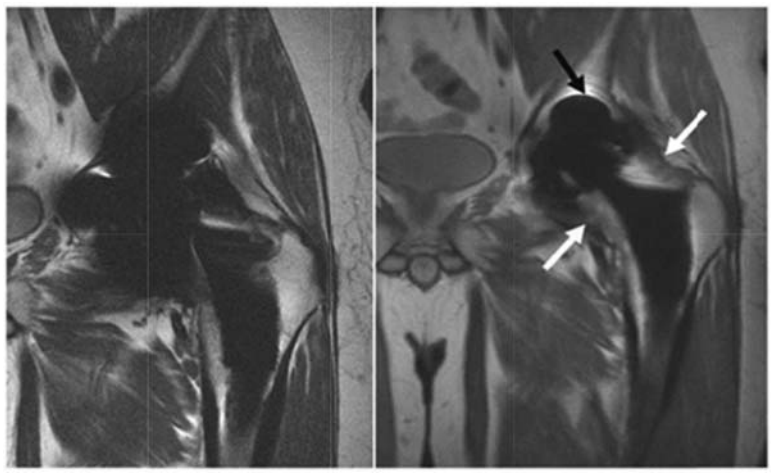

NOTE 1—Note the improved visualization of synovitis (white arrows) and the bone-prosthesis interface (black arrow) on the MAVRIC image. Images courtesy of Dr. Hollis Potter.

FIG. 1 Coronal FSE (left) and MAVRIC (right) Images of a Left MOM Hip Arthroplasty

Documents
Document Sharing Hub

Full document details: ASTM F2978-20

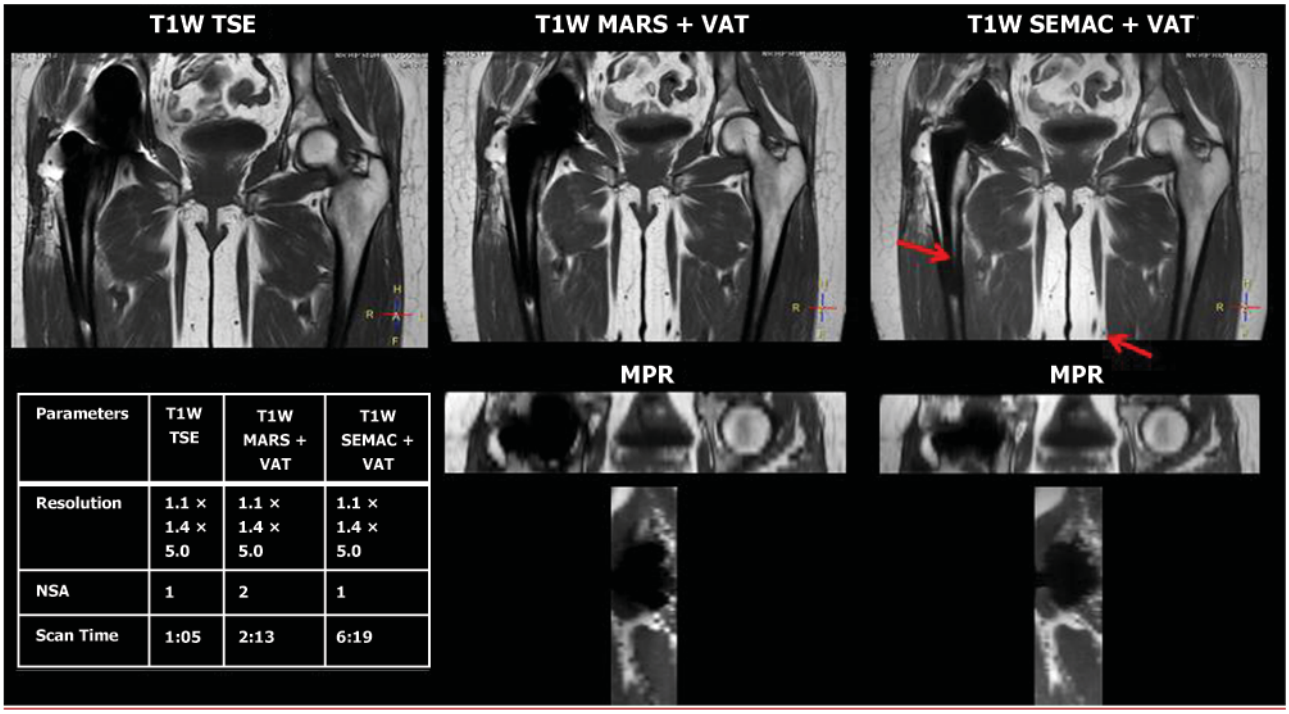

Parameters	T1W TSE	T1W MARS + VAT	T1W SEMAC + VAT
Resolution	1.1 × 1.4 × 5.0	1.1 × 1.4 × 5.0	1.1 × 1.4 × 5.0
NSA	1	2	1
Scan Time	1:05	2:13	6:19

FIG. 2 T1 Weighted TSE (left) and High Bandwidth TSE and VAT (middle), and SEMAC (right) Images of a MOM Hip Arthroplasty

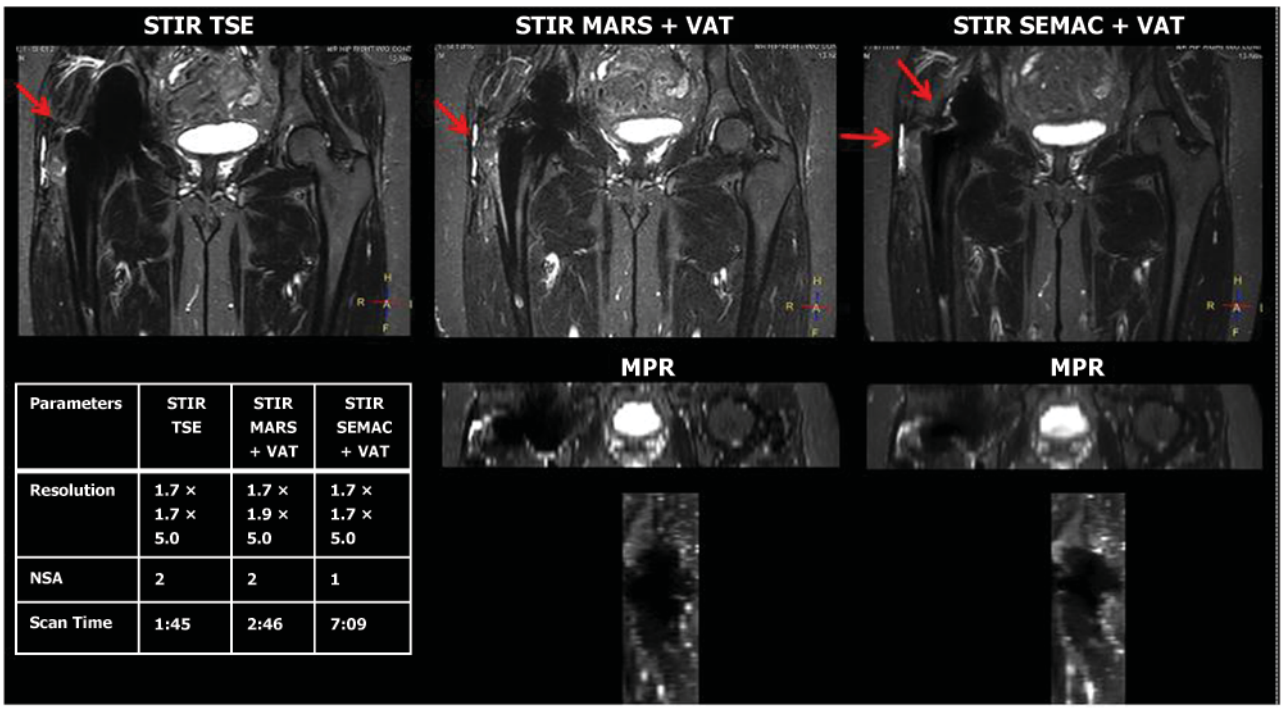

Parameters	STIR TSE	STIR MARS + VAT	STIR SEMAC + VAT
Resolution	1.7 × 1.7 × 5.0	1.7 × 1.9 × 5.0	1.7 × 1.7 × 5.0
NSA	2	2	1
Scan Time	1:45	2:46	7:09

FIG. 3 STIR (T2 Weighted for Selective Visualization of Fluid Accumulation) TSE (left) and High Bandwidth TSE and VAT (middle), and SEMAC (right) Images of a MOM Hip Arthroplasty

is in contrast to a well-fixed component, with high signal intensity fatty marrow directly opposed to the implant interface.

5.3.3 *Wear-Induced Synovitis*—Magnetic resonance imaging is the most useful imaging modality to assess the intracapsular burden of wear-induced synovitis surrounding MOM arthroplasty (23). Preliminary data indicate that the signal characteristics of the synovial response on MR imaging correlate with the type of wear-induced synovitis demonstrated on histology at revision surgery (24). Low signal intensity debris is suggestive of metallic debris on histology. Mixed intermediate and low signal debris correlate with the presence of

AVA Documents
Document Sharing Hub

Full document details: ASTM F2978-20